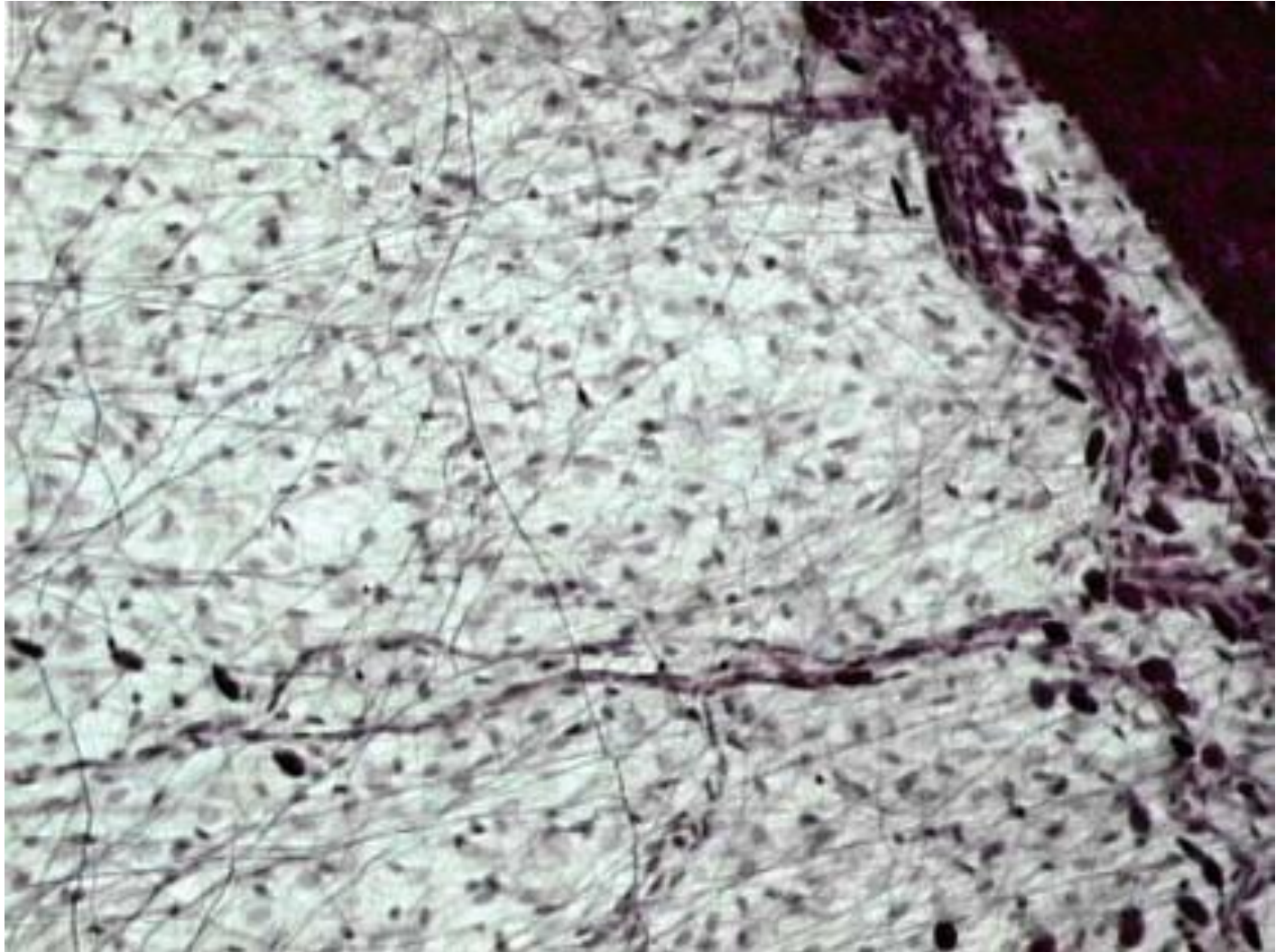
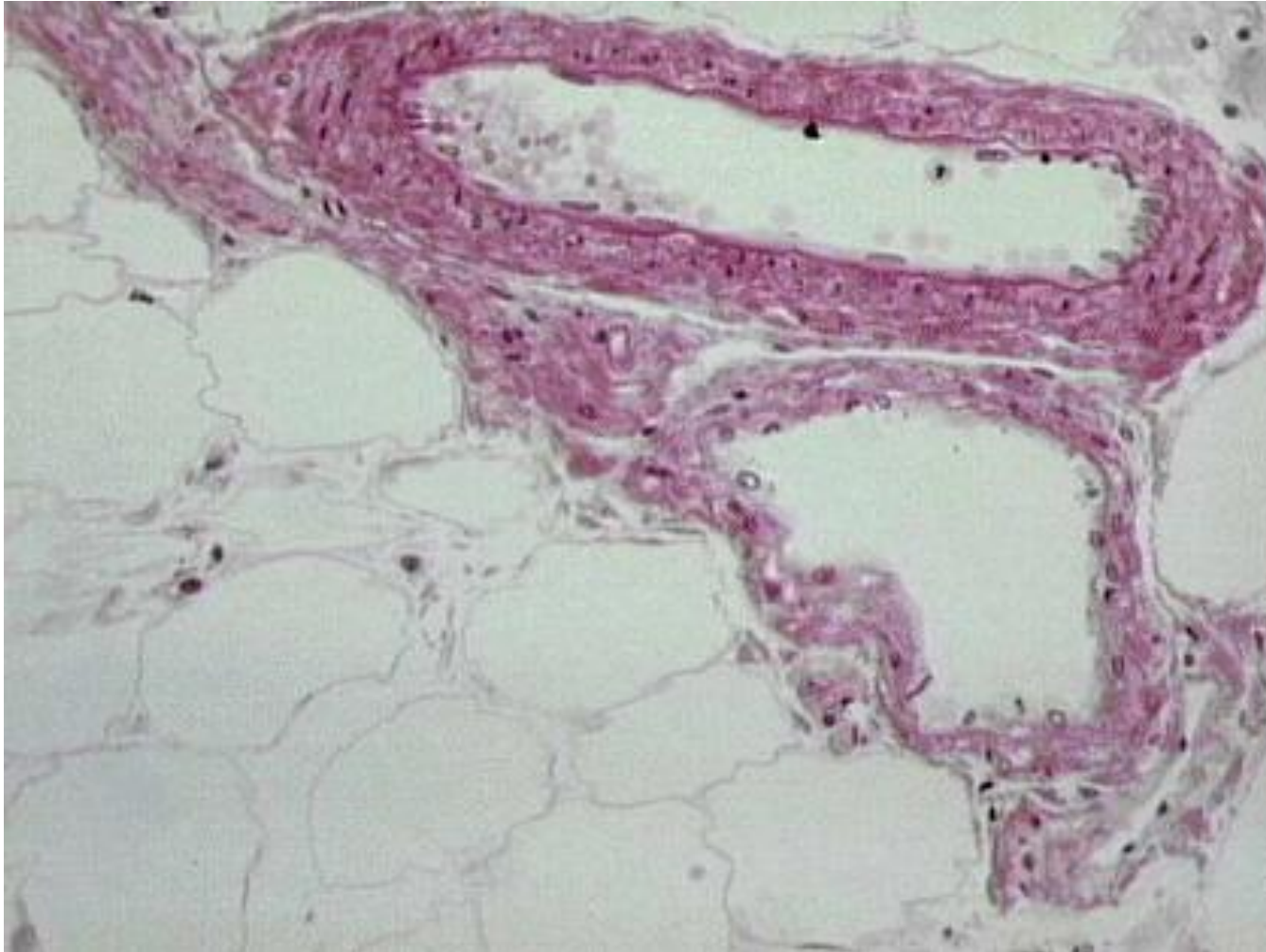


Connective Tissue Slides

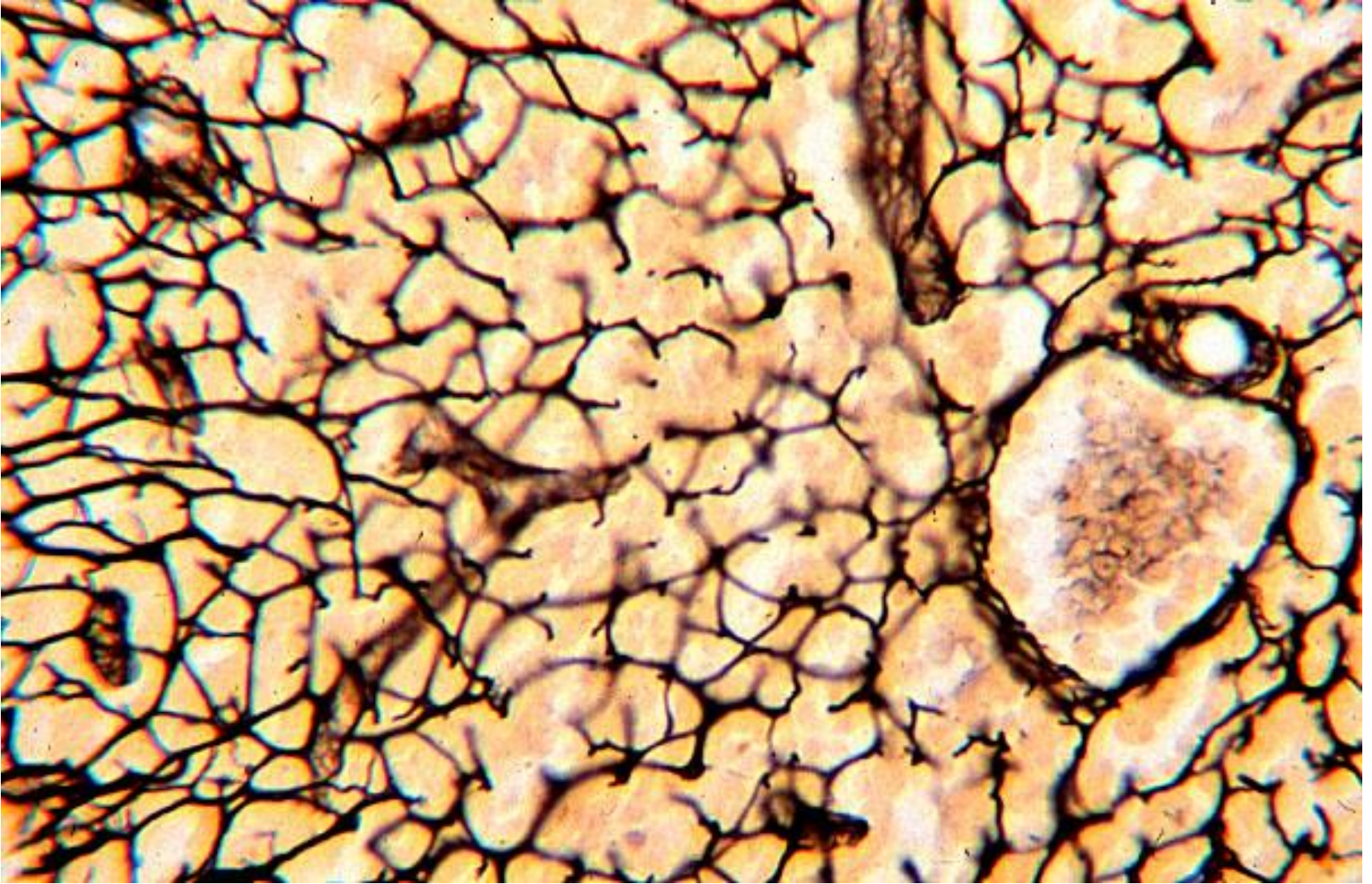
Areolar



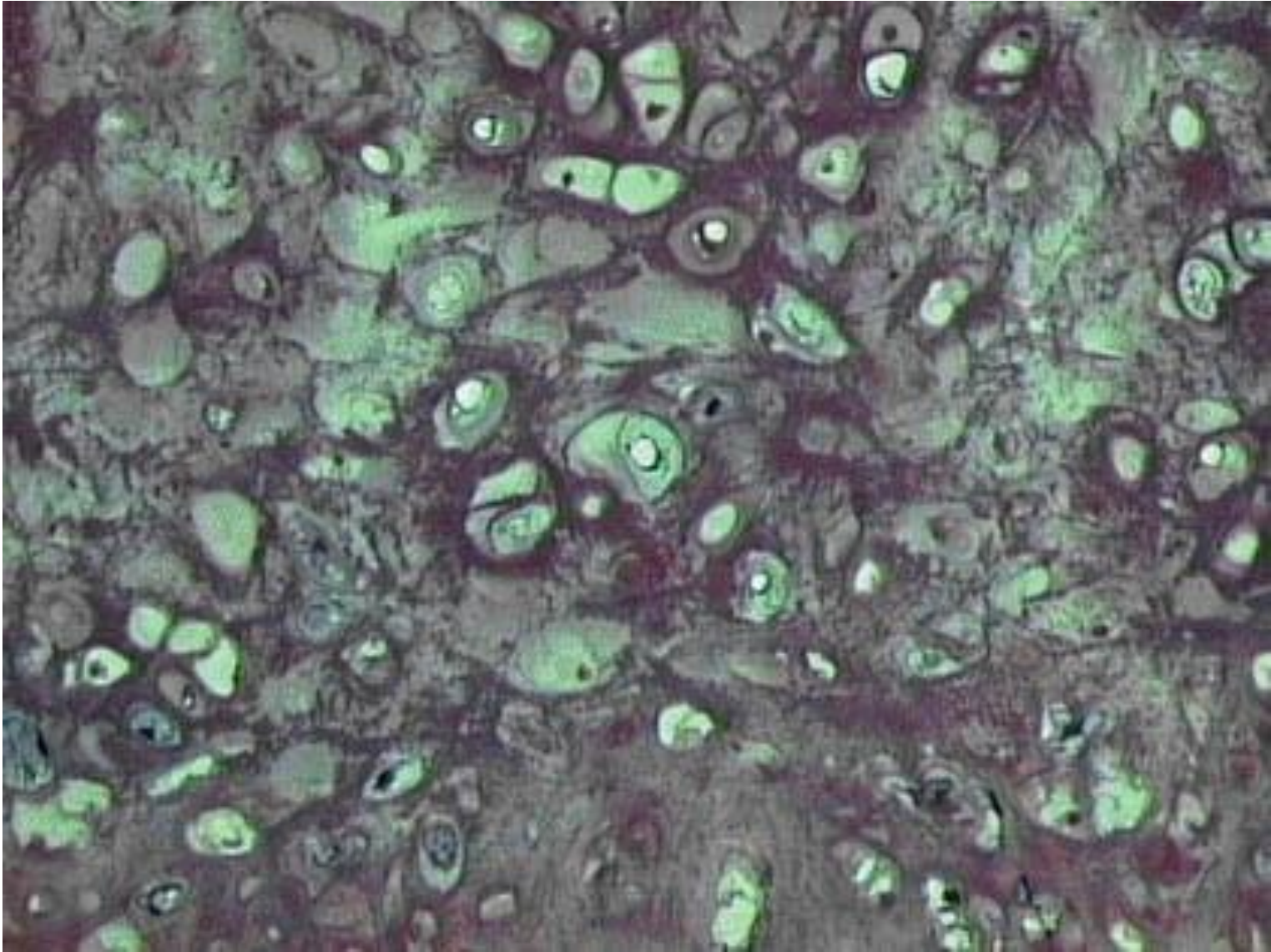
Adipose



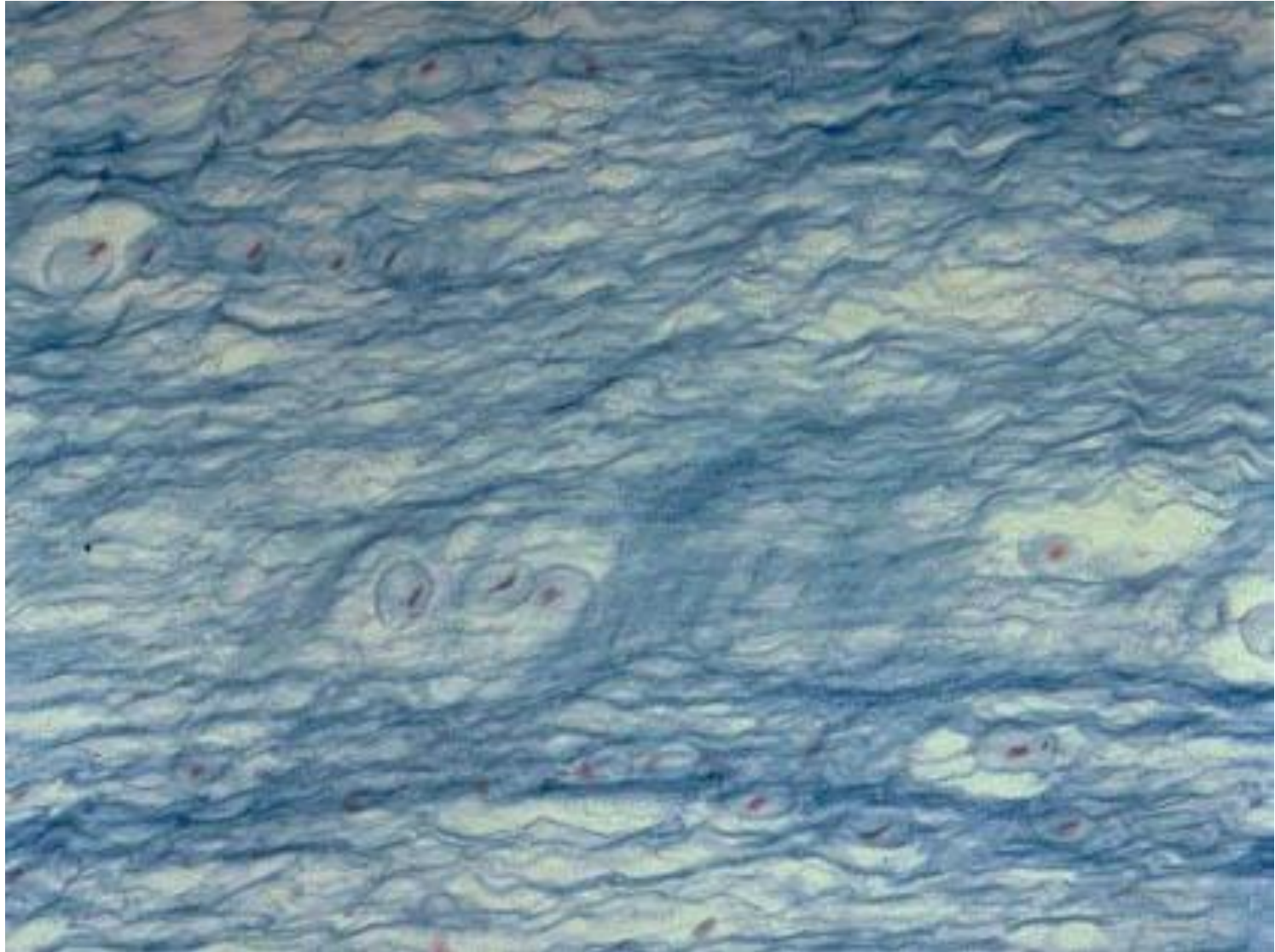
Reticular



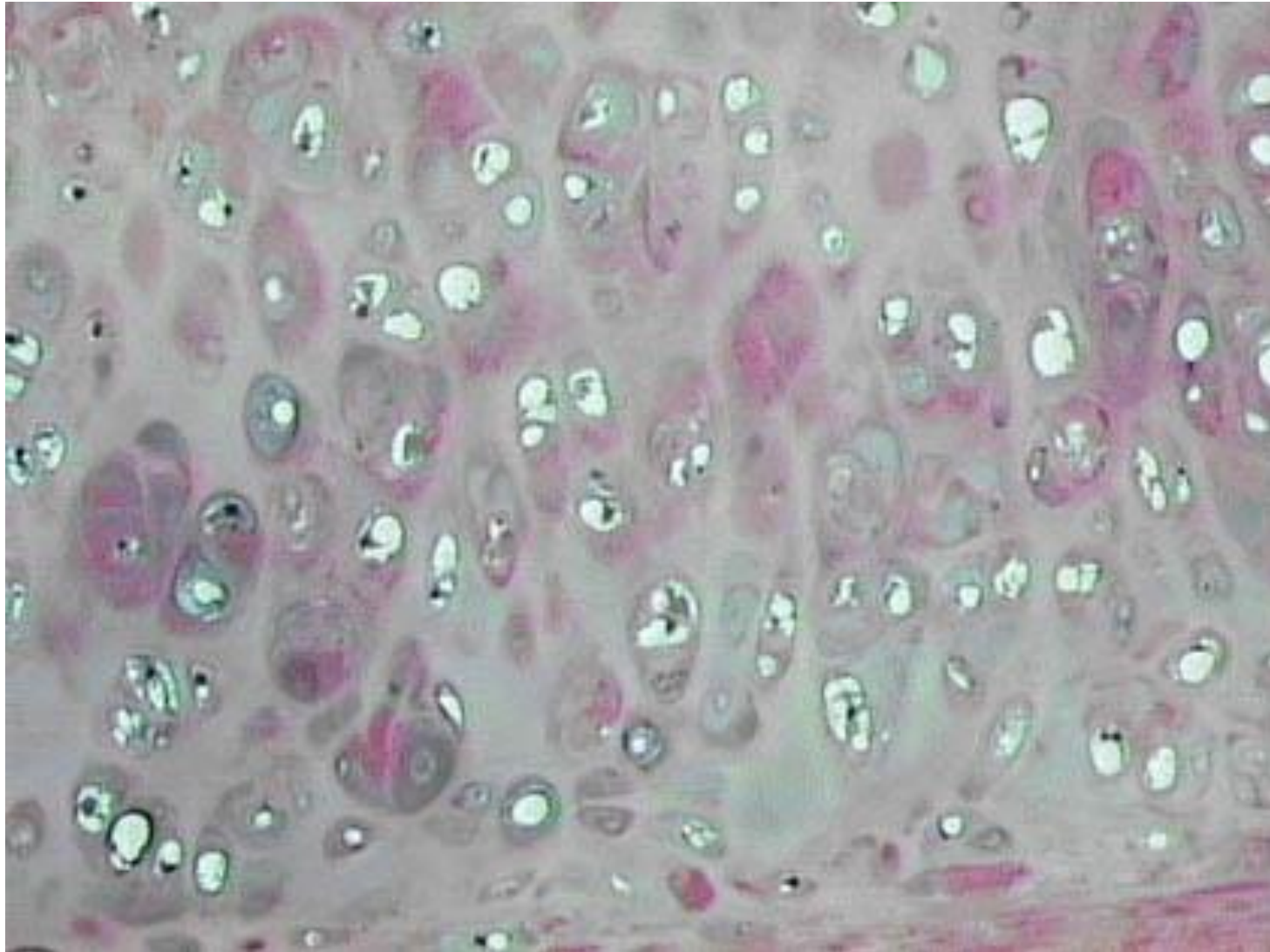
Elastic Cartilage



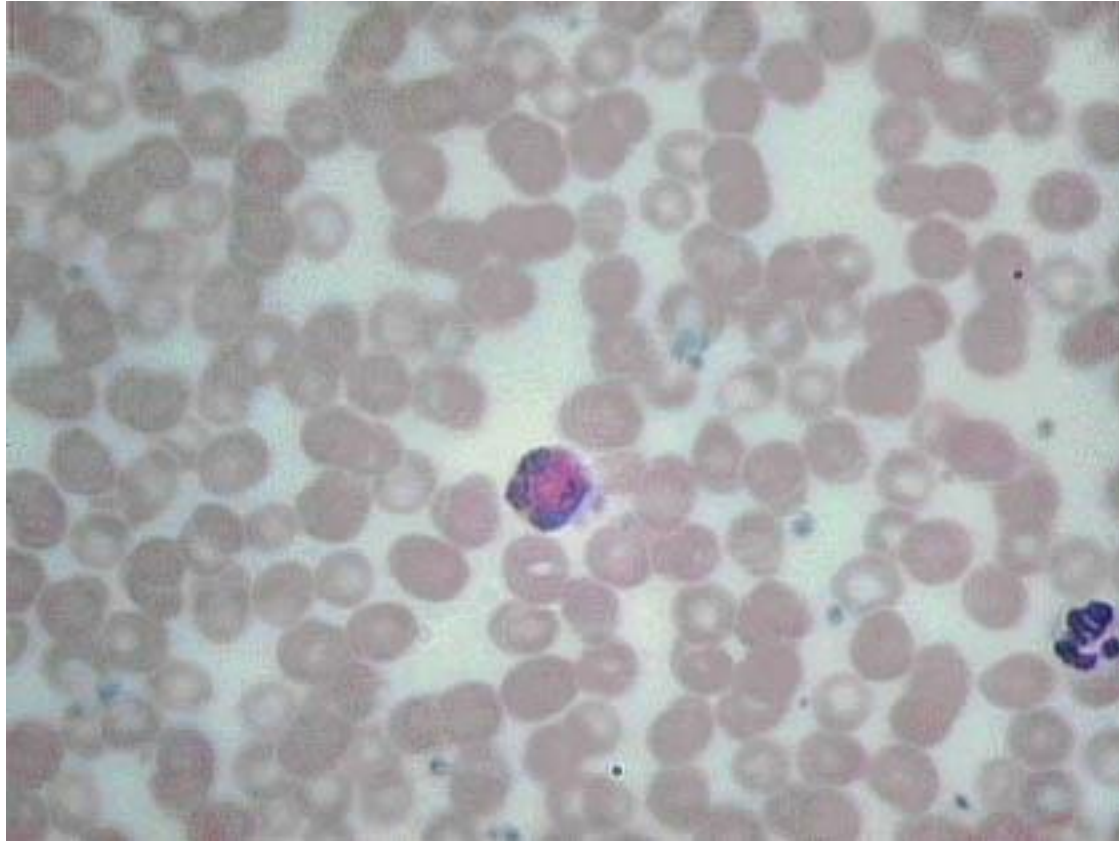
Fibrocartilage



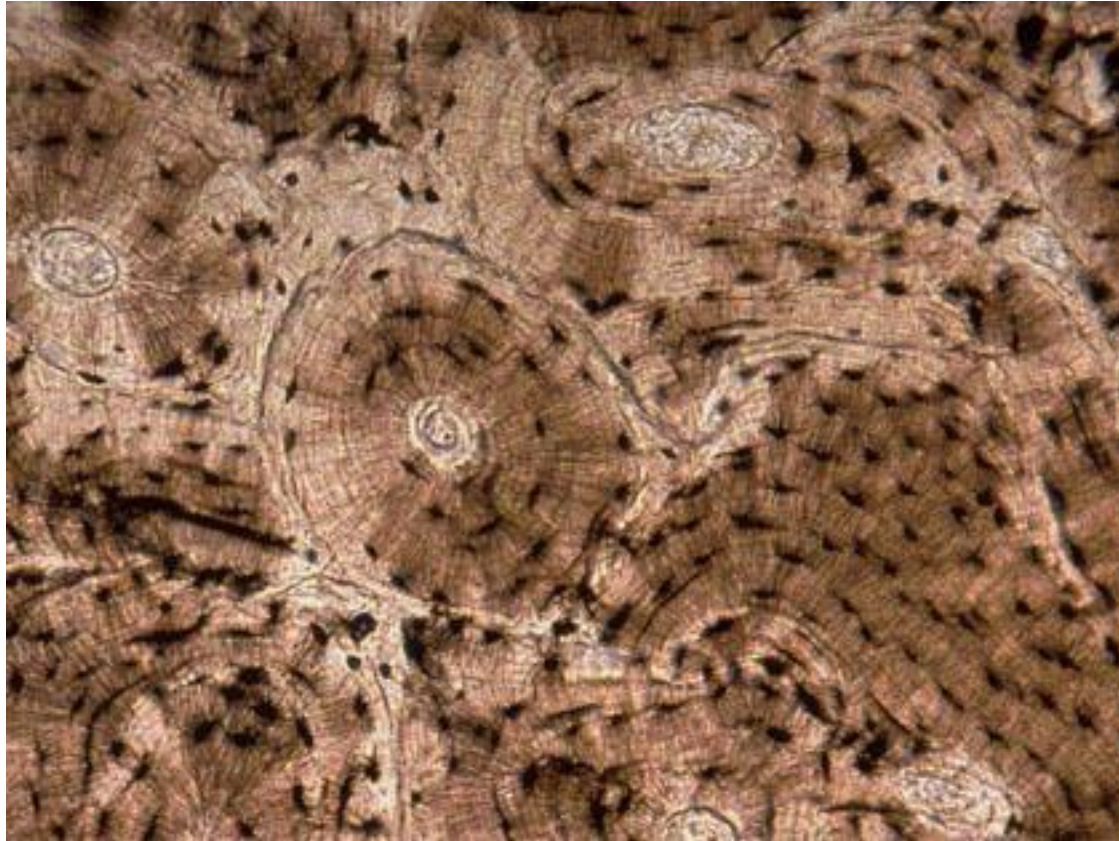
Hyaline Cartilage



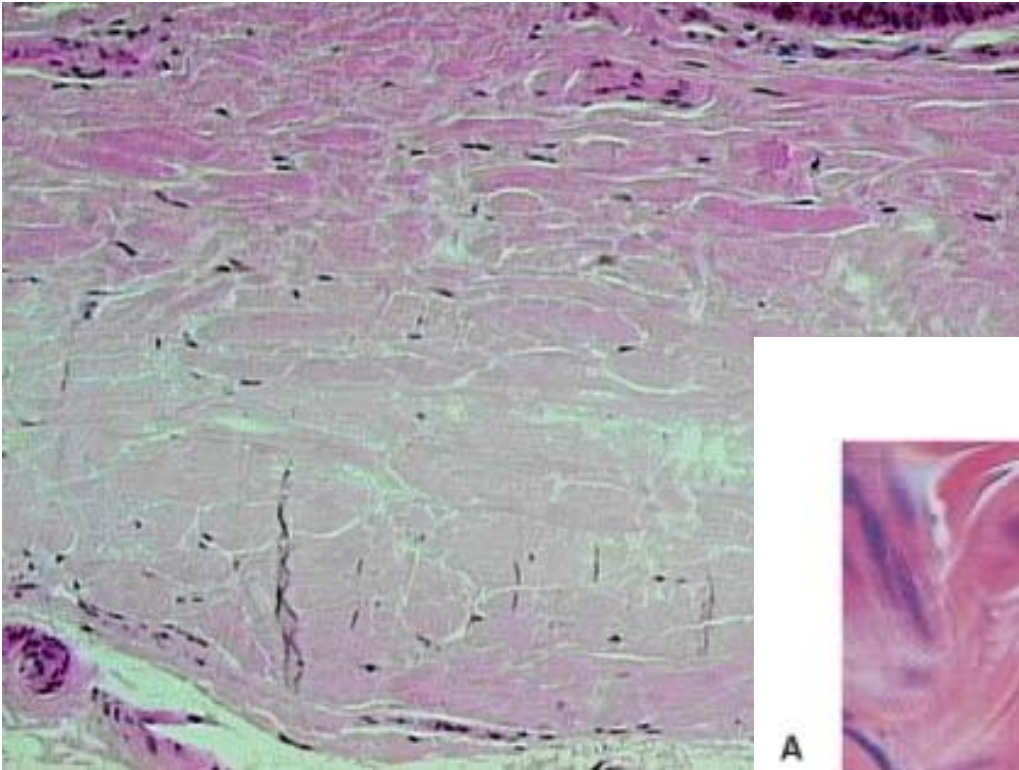
Blood



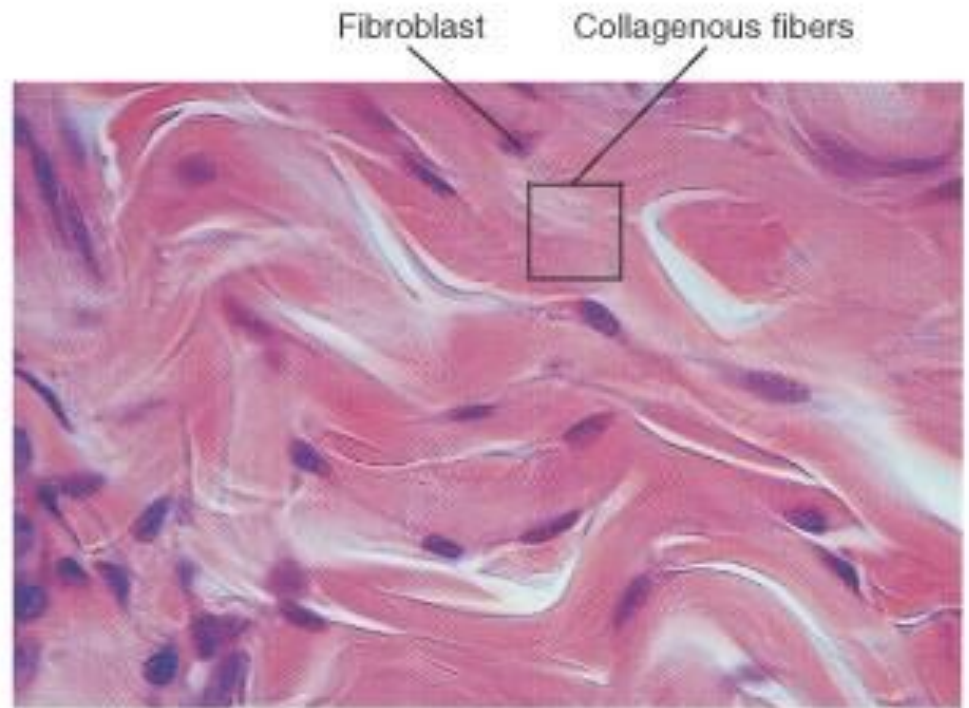
Compact (Osseous) Bone




Dense Irregular



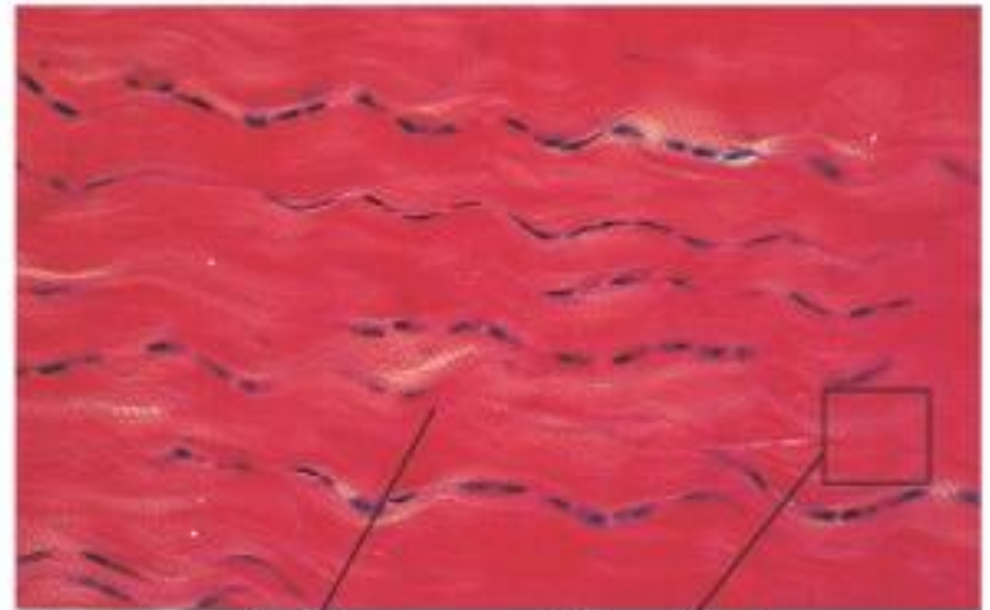A



Dense Regular



A

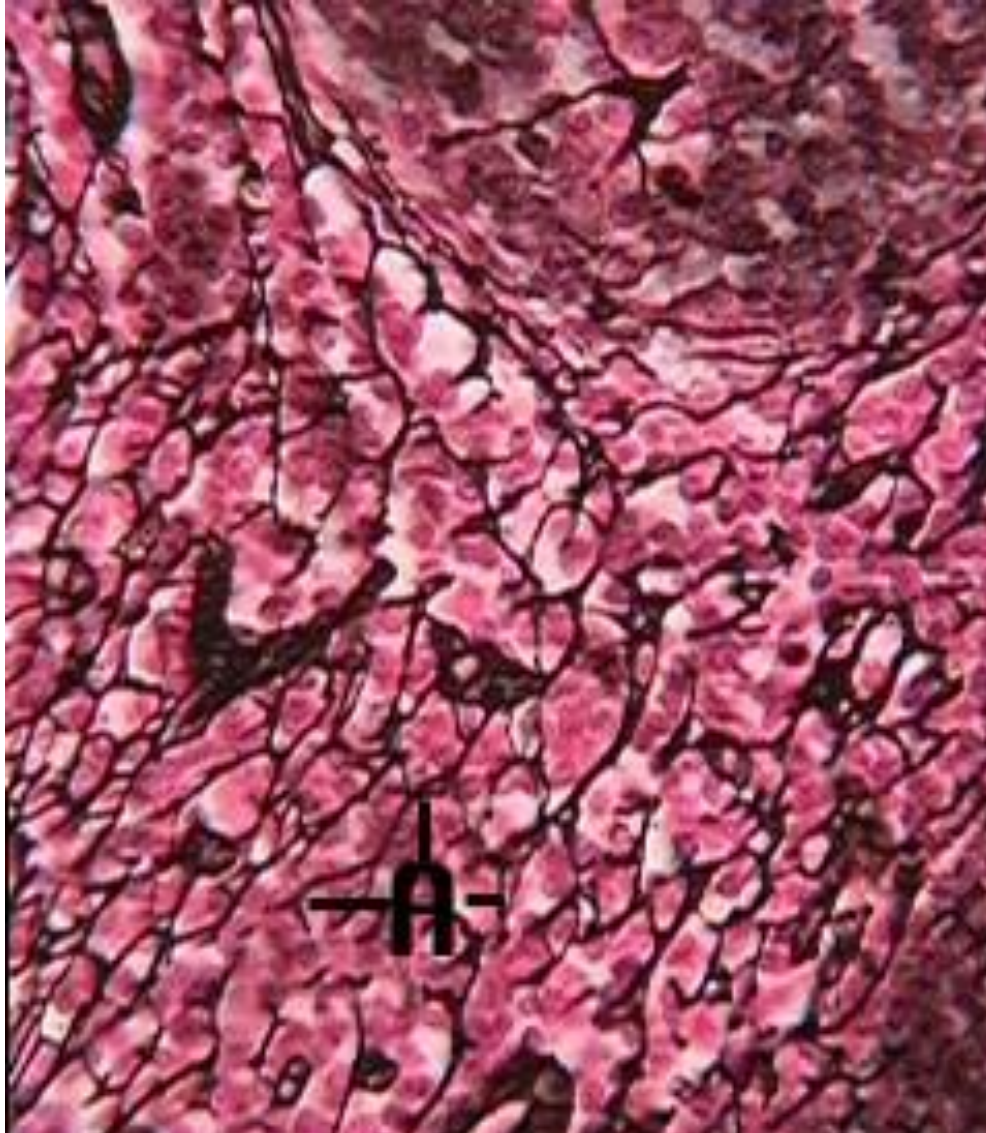


Fibroblast

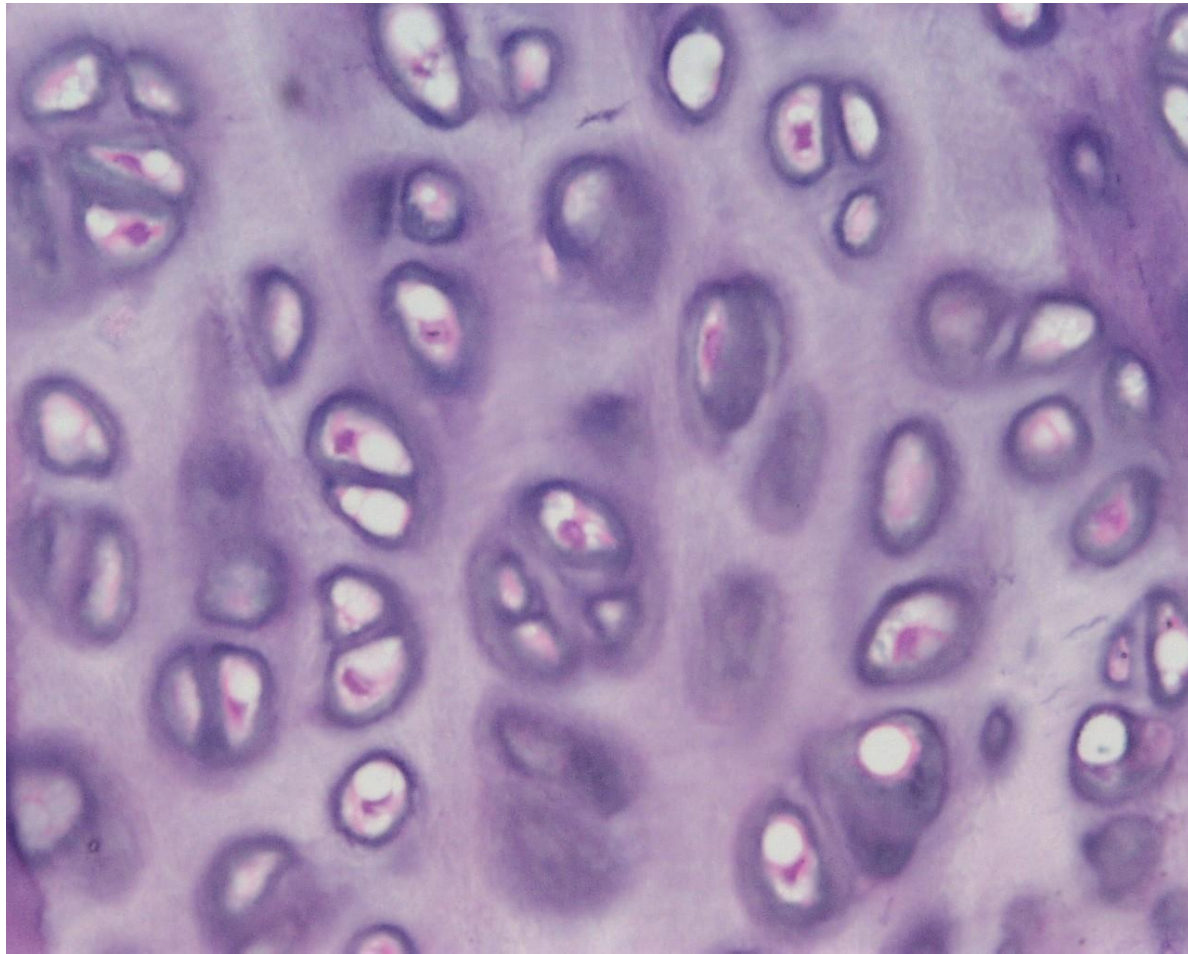
Collagenous fibers

CT Practice

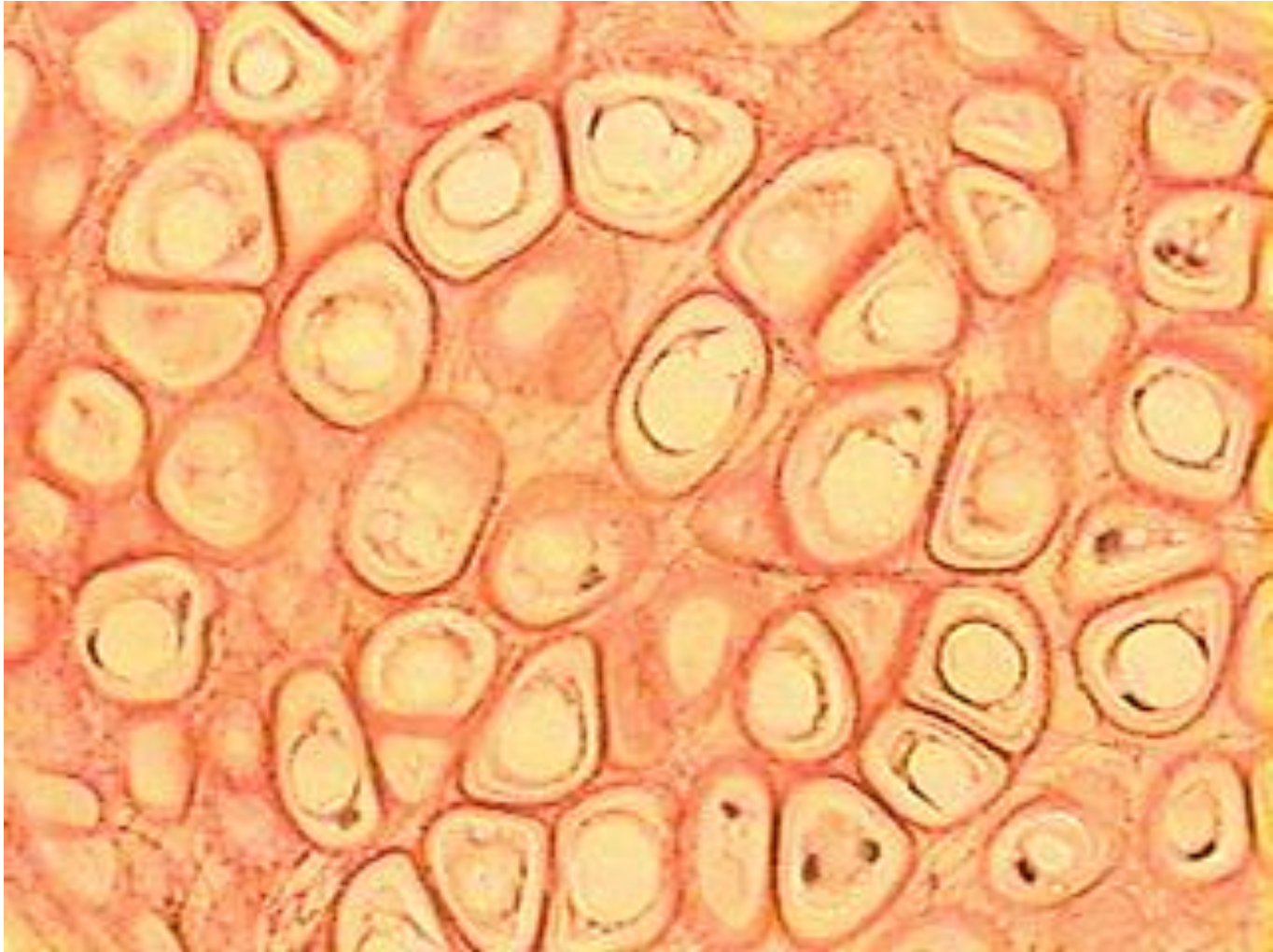
#1



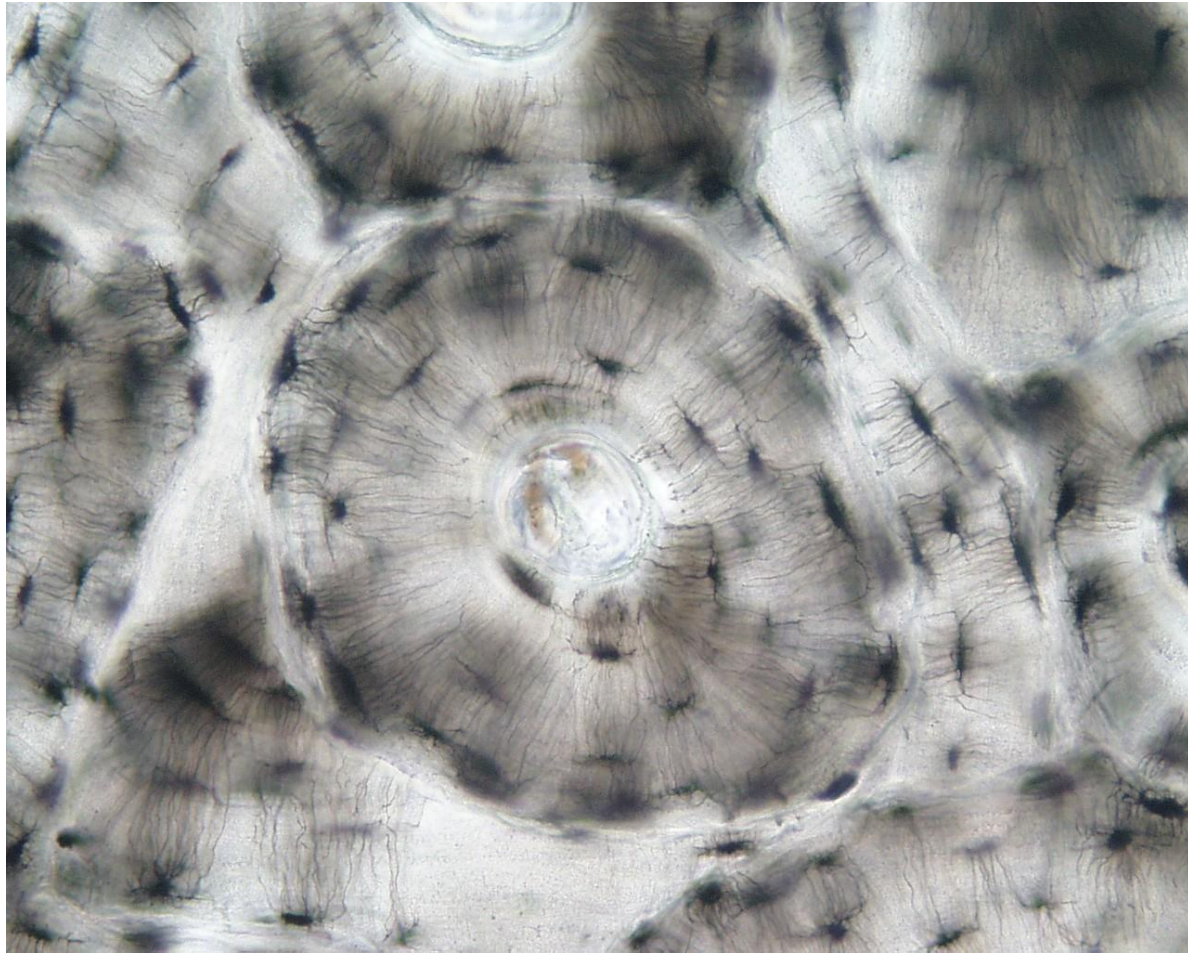
#2



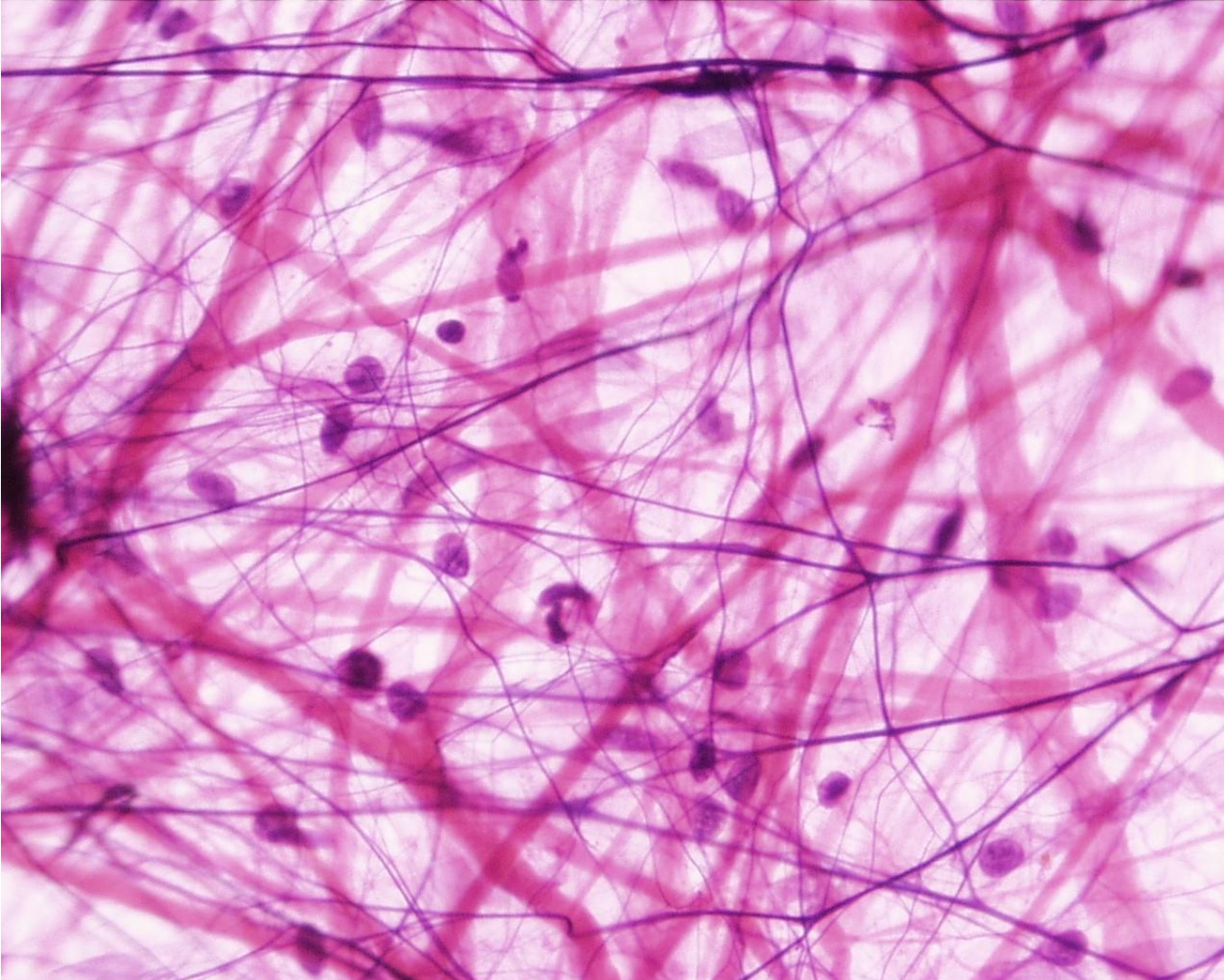
#3



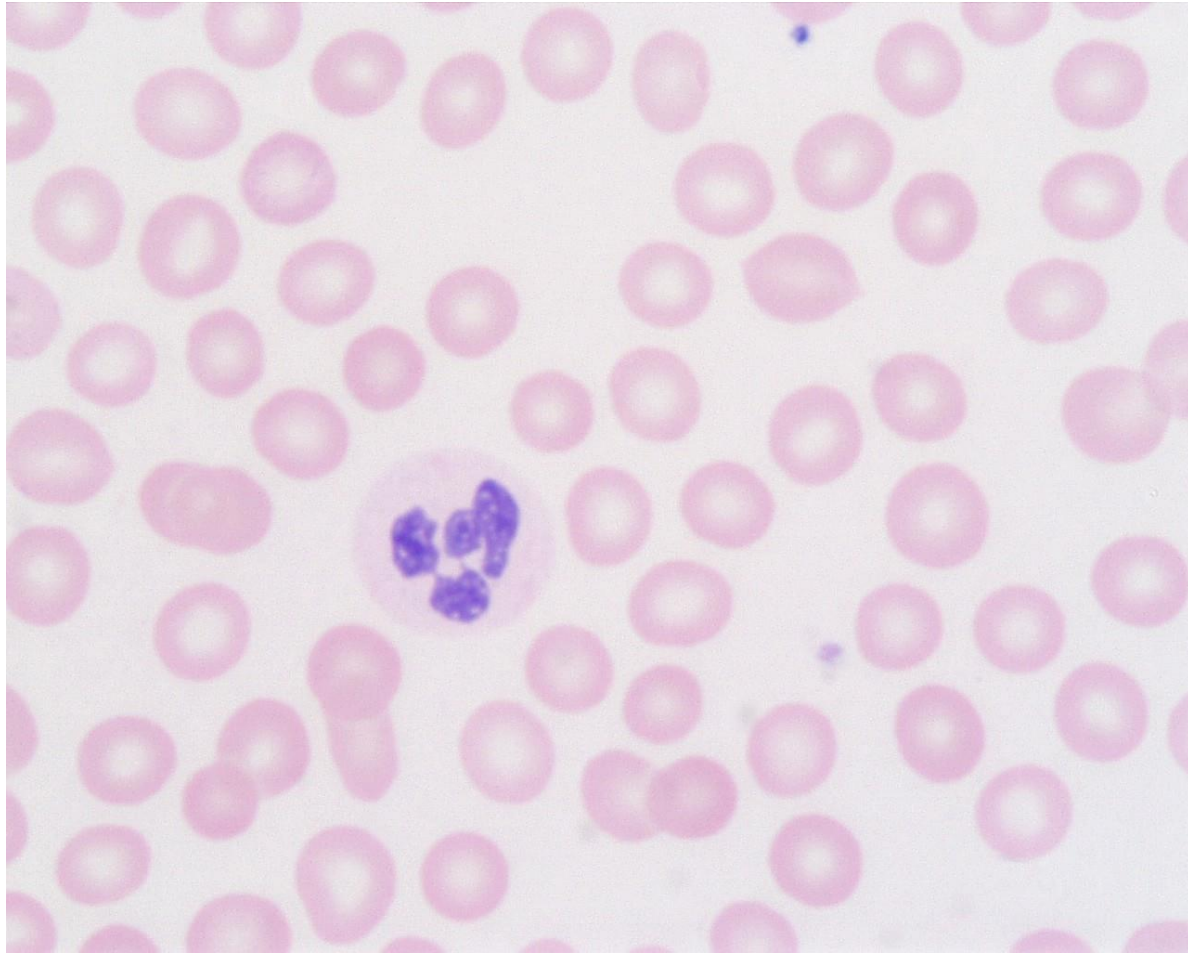
#4



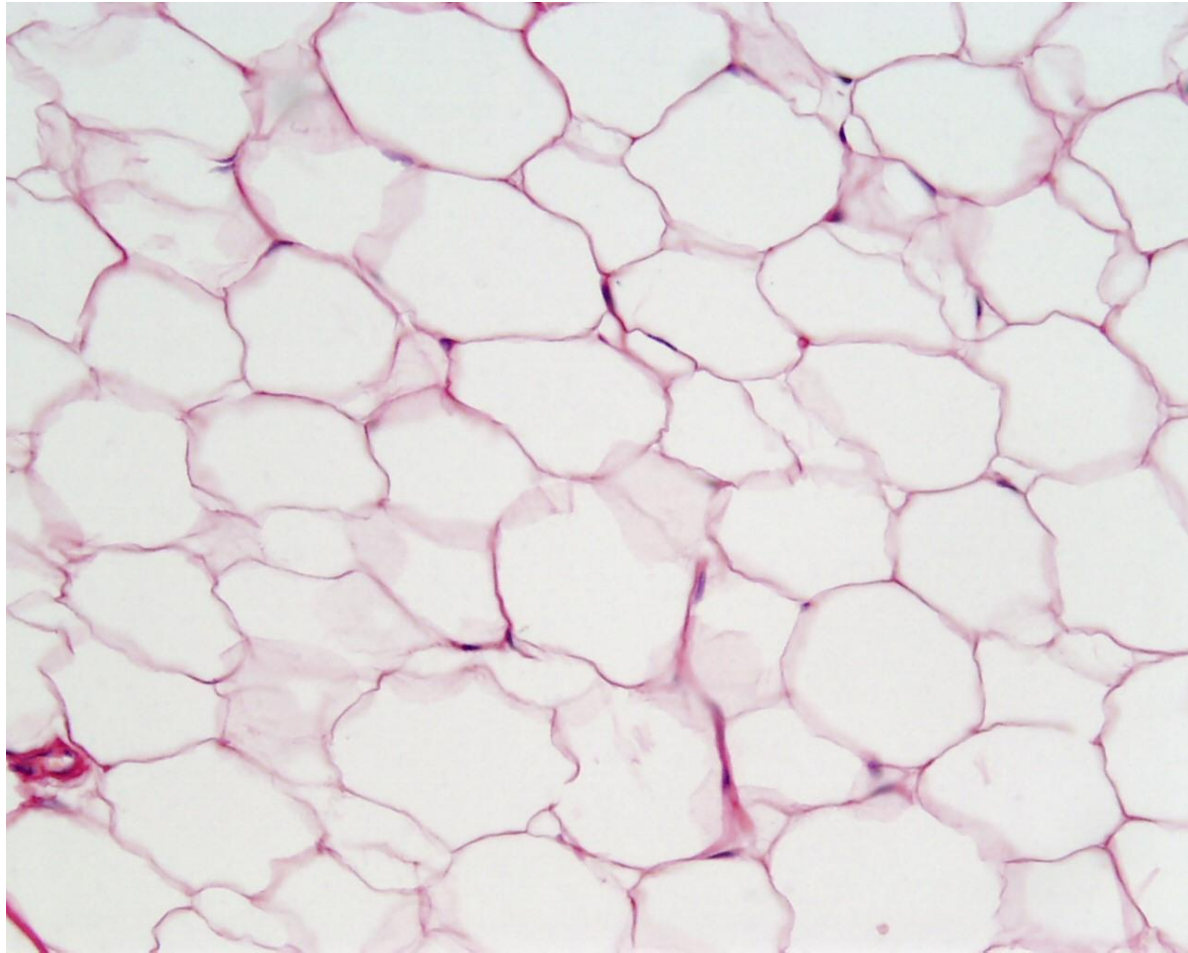
#5



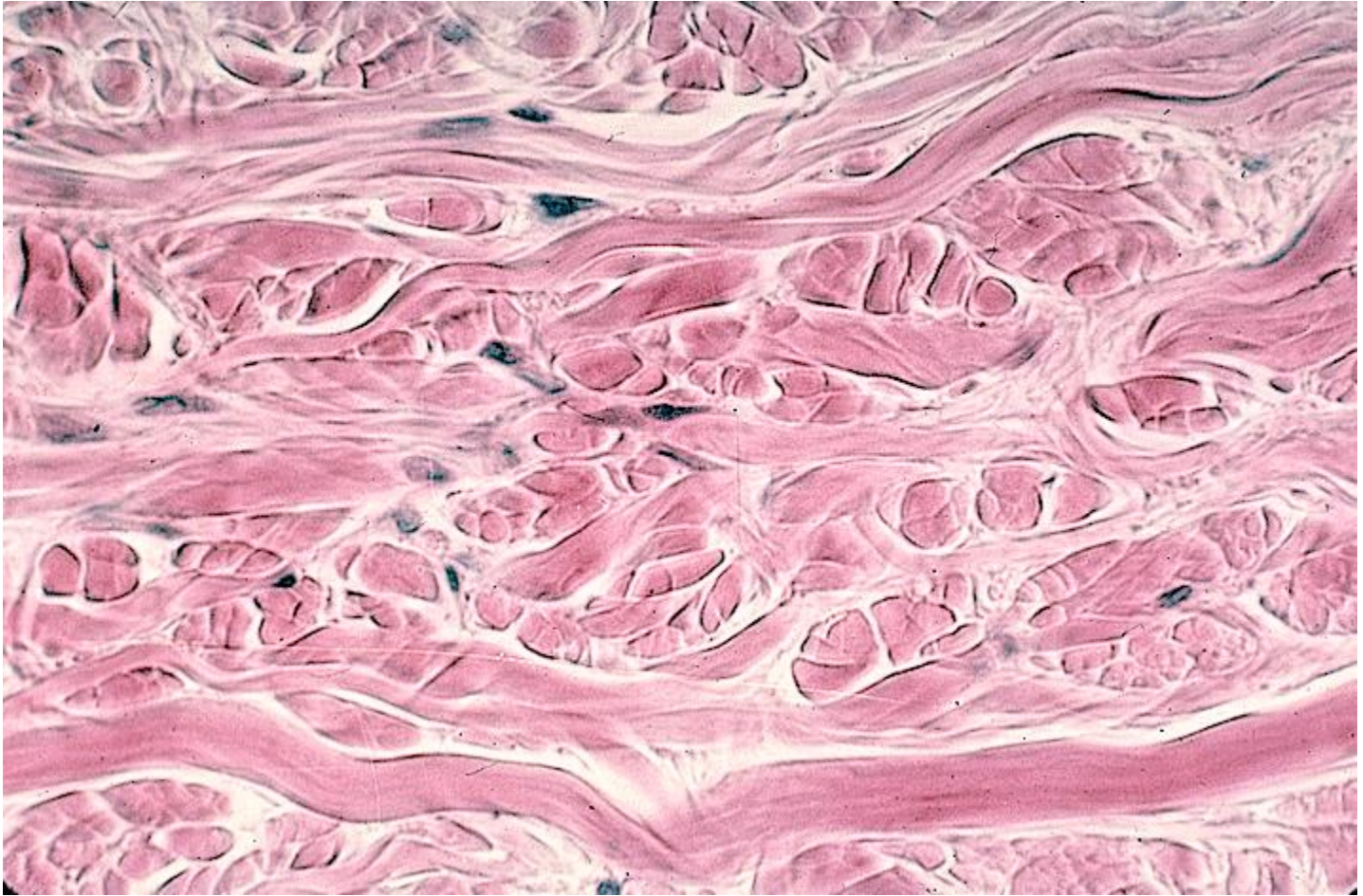#6



#7



#8



#9



Answers

- 1. reticular
- 2. hyaline cartilage
- 3. elastic cartilage
- 4. osseous bone
- 5. areolar
- 6. blood
- 7. adipose
- 8. dense irregular
- 9. dense regular